

Case Study

Parotid Oncocytoma in Birt-Hogg-Dubé Syndrome: A New Pitfall in ¹⁸F-Fluorodeoxyglucose Positron Emission Tomography/Computed Tomography Imaging Study

Sethu Thakachy Subha^{1*}, Abdul Jalil Nordin², Norhafizah Mohtarrudin³ and Fathinul Fikri Ahmad Saad²

¹Department of Surgery/ENT, Faculty of Medicine Health Sciences, Universiti Putra Malaysia, 43400 UPM Serdang, Selangor, Malaysia

²Centre for Diagnostic Nuclear Imaging, Universiti Putra Malaysia, 43400 UPM Serdang, Selangor, Malaysia

³Faculty of Medicine Health Sciences, Universiti Putra Malaysia, 43400 UPM Serdang, Selangor, Malaysia

ABSTRACT

Oncocytomas are rare head and neck neoplasms that occur most commonly in the parotid salivary gland. Birt-Hogg-Dubé syndrome is a rare inherited genodermatosis manifested by a group of cutaneous lesions, in association with several renal and lung pathology, parotid oncocytoma, thyroid and colonic tumours. Here we report on the case of a patient who presented with parotid oncocytoma in association with skin lesions, multinodular goitre and uterine leiomyoma. This array of lesions suggested the possibility of Birt-Hogg-Dubé syndrome. ¹⁸F-Fluorodeoxyglucose Positron Emission Tomography/Computed Tomography (¹⁸F FDG PET/CT) was used to evaluate head and neck malignancies, including salivary gland tumours. In this report, we highlight a case of bilateral parotid oncocytoma with suspected Birt-Hogg-Dubé syndrome that showed increased FDG uptake in a PET-CT study. This marked FDG avidity in a benign parotid oncocytoma, adding to the list of common pitfalls related to the parotid glands during a FDG PET-CT study.

Keywords: Oncocytoma, parotid gland, ¹⁸F FDG PET CT (¹⁸F-Fluorodeoxyglucose Positron Emission Tomography/Computed Tomography), BHD (Birt-Hogg-Dubé Syndrome)

Article history:

Received: 8 January 2015

Accepted: 2 June 2015

E-mail addresses:

subhast2@yahoo.com (Sethu Thakachy Subha),

drimaging@yahoo.com (Abdul Jalil Nordin),

norhafizahm@upm.edu.my (Norhafizah Mohtarrudin),

ainurff@gmail.com (Fathinul Fikri Ahmad Saad)

*Corresponding author

INTRODUCTION

Oncocytomas of the salivary glands are rare benign epithelial tumours that comprise less than 1% of salivary gland tumours. The parotid gland is the most commonly affected salivary gland, accounting for 78-84% of

salivary gland oncocytoma, while bilateral presentation is reported to be extremely rare (Tana *et al.*, 2010; Uzunkulaoglu *et al.*, 2012). Birt-Hogg- Dubé syndrome is a rare autosomal dominant condition characterised by a group of cutaneous lesions, in association with several renal and lung pathology, parotid oncocytoma, thyroid and colonic tumours (Liu *et al.*, 2000; Adley *et al.*, 2006; López *et al.*, 2012).

¹⁸F FDG PET CT is an integrated imaging modality that has been vastly utilised in investigation and management of head and neck tumours. This multimodality diagnostic imaging positron emission tomography computed tomography (PET-CT) is a known improved method for oncology staging in comparison to conventional modalities. The use of 2-[fluorine-18]-fluoro-2-deoxy-D-glucose, a glucose analogue in PET-CT study as a biomarker, facilitates the identification of abnormal tissues with high glycolytic activity, albeit the fact that biological response cannot separate an active benign lesion from malignancy, leading to pitfalls and false positive interpretations of the study.

CASE REPORT

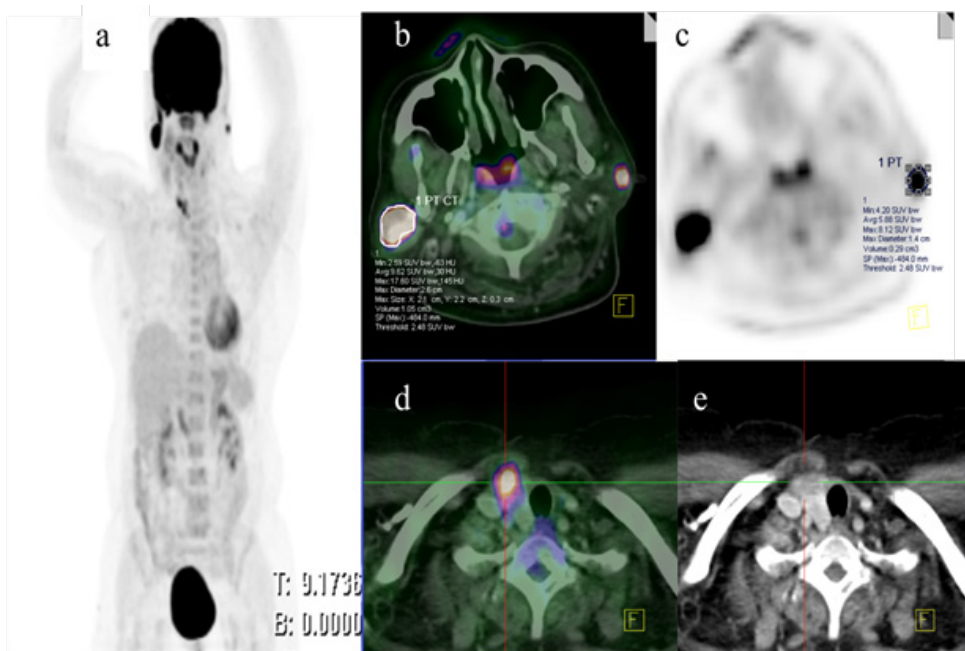


Fig.1: MIP (image a) demonstrate abnormal foci of high FDG uptake in the region of the neck and right upper chest. Integrated fused PET and CT images in the axial plane at the level of the post nasal space (image b) demonstrate increased FDG uptake in both parotids with SUV_{max} 17.6 and 8.1 (image c) in the right and left, respectively. In addition to this finding, there is a foci of high FDG uptake seen in the remnant of the right thyroid lobe (image d), which was reported as normal on initial CT. The corresponding contrasted CT (image e) demonstrates a poorly enhanced low attenuation lesion within the right lobe.

The subject was a 60-year-old woman who had been diagnosed with a progressively increasing right parotid swelling for six months prior to the study. The non-tender swelling was without any other significant clinical signs or symptoms. Her past medical and surgical history revealed that she had skin lesions over the anterior part of the neck many years ago that were excised and informed to be benign lesions. She also underwent a left hemithyroidectomy for multinodular goiter and a hysterectomy for uterine leiomyoma. Meanwhile, an ENT examination showed non-tender firm mass (3 x 4 cm) in the right parotid region. A CT scan demonstrated enhancing lesions in both parotid glands. The right parotid gland was found to be bigger than the left. The right thyroid lobe looked normal.

Further investigation was also carried out on the patient using FDG PET-CT so as to exclude malignancy, mainly lymphoma. The study was conducted following standard protocol. The images were analysed by two nuclear radiologists in a systematic manner at 1 mm reconstruction in axial, coronal and sagittal planes. The imaging results from the PET study were interpreted qualitatively to look for abnormally high FDG uptake lesions and quantitatively using an automated maximum standardised uptake value (SUVmax) derived from the region of interest (ROI) drawn over FDG avid lesions. The CT images were analysed for any abnormal morphology and enhancing patterns. Eventually, both the PET and CT images were fused and interpreted together. The study showed ill-defined enhancing mass lesions arising from both parotid glands. Both the parotid lesions demonstrated high FDG uptake. The metabolism of the lesions was semi-quantified through the region of interest drawn over the lesions and represented as 17.6 and 8.2 in the right and left, respectively. In addition, there was a focus of high FDG uptake in the remnant of the right thyroid lobe without morphological change with the maximum standardised uptake value (SUVmax) of 14.8. The lesion enhanced well and homogeneously following intravenous contrast administration. The morphological changes found at imaging, in combination with high metabolic activity, aroused suspicions for malignancy within the glands; thus, a fine needle aspiration procedure was conducted for the parotids and thyroid lesions. Meanwhile, a cytological smear from the parotid lesions demonstrated clusters of round to polygonal shaped cells, with small monomorphic nuclei and coarse granular cytoplasm on Diff Quick stain (see Fig.2). These features are highly suggestive of parotid oncocytoma. Ultrasound guided FNA of the right thyroid showed granulomatous thyroiditis. There were no lesions found in the lung parenchyma and both kidneys by PET-CT imaging. It is important to note that the patient refused any further surgical intervention.

DISCUSSION

Oncocytomas are rare head and neck neoplasms that occur most commonly in parotid salivary gland. Oncocytoma, which is also known as oxyphilic adenoma, is a benign neoplasm that clinically presents as solid, well circumscribed nodules. These tumours are usually seen in the elderly and affect the parotid gland in 80% of related cases (Tana *et al.*, 2010; Uzunkulaoglu *et al.*, 2012). Birt-Hogg- Dubé syndrome is a rare autosomal dominant condition that consists of fibrofolliculomas, trichodiscomas and acrochordons. It is also associated with several non-cutaneous tumours. Various reports have revealed that these constellations of cutaneous lesions are associated with parotid oncocytoma, multinodular goiter and lipoma, as well as

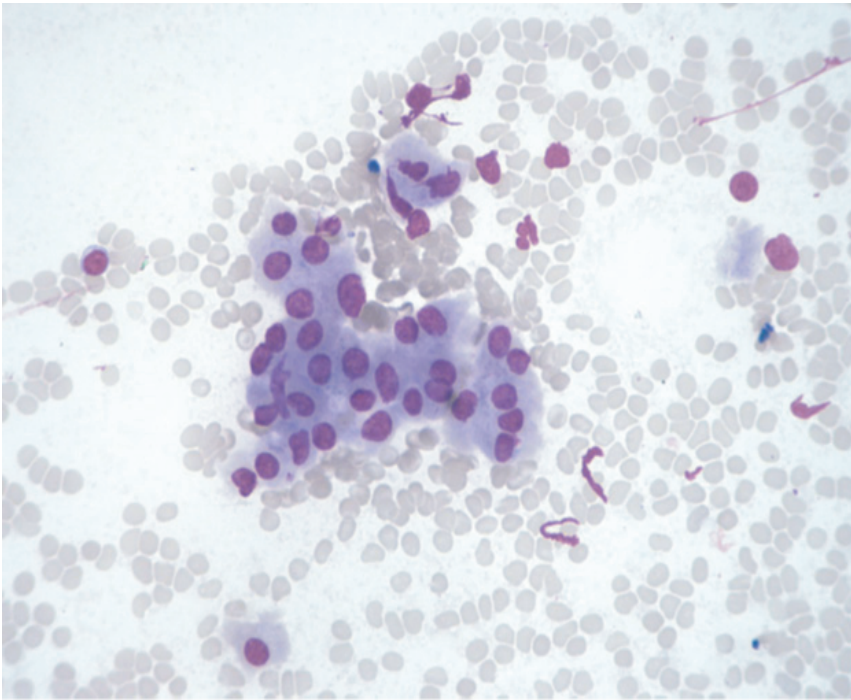


Fig.2: Oncocytoma. The neoplastic oncocytic epithelium is arranged in clusters. The cells are round to oval monomorphic nuclei with abundant densely granular cytoplasm. (Diff Quick. Original magnification $\times 400$).

several renal and lung pathology (Liu *et al.*, 2000; Adley *et al.*, 2006; Menko *et al.*, 2009). However, the actual incidence of Birt-Hogg-Dubé syndrome is unknown, and it is most likely under-diagnosed. In this study, we reported a patient with parotid oncocytoma associated with multinodular goitre, uterine leiomyoma and history of skin lesions. The possibility of the Birt-Hogg-Dubé syndrome was considered in view of constellation of these lesions. CT scan is a well-established first line imaging modality that has been widely used in diagnoses of salivary gland tumours. The common CT findings of parotid oncocytoma described in the literature are that it is a well-defined mass with homogenous enhancement (Shellenberger *et al.*, 2008; Tana *et al.*, 2010). The important differential diagnoses for well-defined enhancing parotid lesions detected in CT include Warthin's tumour and basal cell adenomas. Pleomorphic adenoma, the most common parotid neoplasm, demonstrates minimal or no enhancement. Hence, it is less likely to be the differential diagnosis in this case. A low-grade parotid malignancy is an important differential diagnosis and a major diagnostic pitfall in the imaging assessment of a well-defined enhancing parotid tumour. MR imaging allows markedly improved soft tissue delineation and thus, helps to characterise parotid gland mass lesions. Oncocytomas appear hypointense and well demarcated on T1 but are isointense to the native parotid gland on fat-saturated T2 and T1 post contrast imaging (Patel *et al.*, 2011). 18F FDG PET CT has been shown to be superior to conventional imaging in evaluating patients with head and neck tumours. However, non-specificity of FDG uptake in benign lesion has led to false positive findings in the interpretation of the results, as in this case (Shah *et al.*, 2007; Uzunkulaoglu *et al.*, 2012)

Fine Needle Aspiration (FNA) is an investigation of choice for making a diagnosis in the majority of cases (Vlachaki *et al.*, 2009; Uzunkulaoglu *et al.*, 2012). Likewise, in this case, the aspirates confirmed the diagnosis of oncocytoma. The smears showed oncocytes with no evidence of atypia. The presence of marked atypical oncocytes suggests the possibility of an oncocytic carcinoma. However, oncocytic carcinoma cannot be distinguished reliably from oncocytoma on FNA because diagnosis of malignancy is based on either local invasion or metastasis. Oncocytoma generally presents as a solid, well circumscribed mass characterised as having a tan colour. Microscopically, it is composed of large cells with round nuclei and abundant granular acidophilic cytoplasm (Vlachaki *et al.*, 2009). Mitotic figures are absent. The malignant counterpart of oncocytoma is oncocytic carcinoma. It is characterised by cellular atypia, increased mitotic activity and infiltrative growth (Shah *et al.*, 2007; Menko *et al.*, 2009). Ki-67 immunostaining has been used to differentiate benign from malignant oncocytoma. The treatment of choice for these tumours is mainly surgical. It is mandatory to identify the extent and nature of tumours prior to any definitive surgical treatment (Vlachaki *et al.*, 2009; Tana *et al.*, 2010; Uzunkulaoglu *et al.*, 2012).

CONCLUSION

Oncocytic neoplasms should be considered as a possible diagnosis in elderly patients with parotid enlargement. It is important to conduct a histological investigation before finalising any diagnosis of FDG avid lesion within parotid glands since FDG is a non-specific tracer.

REFERENCES

- Adley, B. P., Smith, N. D., Nayar, R., & Yang, X. J. (2006). Birt-Hogg-Dubé Syndrome. Clinicopathologic findings and genetic alterations. *Archives of Pathology and Laboratory Medicine*, 130, 1865-1870.
- Kunogi, M., Kurihara, M., Ikegami, T. S., Kobayashi, T., Shindo, N., Kumasaka, T., ... & Seyama, K. (2010). Clinical and genetic spectrum of Birt-Hogg-Dubé syndrome patients in whom pneumothorax and/or multiple lung cysts are the presenting feature. *Journal of medical genetics*, 47(4), 281-287.
- Liu, V., Kwan, T., & Page, E. H. (2000). Parotid oncocytoma in the Birt-Hogg-Dubé syndrome. *Journal of the American Academy of Dermatology*, 43(6), 1120-1122.
- López, V., Jordá, E., & Monteagudo, C. (2012). Birt-Hogg-Dubé Syndrome: An Update. *Actas Dermo-Sifiliográficas (English Edition)*, 103(3), 198-206.
- Maffe, A., Toschi, B., Circo, G., Giachino, D., Giglio, S., Rizzo, A., ... & Genuardi, M. A. U. R. I. Z. I. O. (2011). Constitutional FLCN mutations in patients with suspected Birt-Hogg-Dubé syndrome ascertained for non-cutaneous manifestations. *Clinical Genetics*, 79(4), 345-354.
- Menko, F. H., van Steensel, M. A., Giraud, S., Friis-Hansen, L., Richard, S., Ungari, S., ... & European BHD Consortium. (2009). Birt-Hogg-Dubé syndrome: diagnosis and management. *The Lancet Oncology*, 10(12), 1199-1206.
- Mukunyadzi, P. (2002). Review of fine-needle aspiration cytology of salivary gland neoplasms, with emphasis on differential diagnosis. *American Journal of Clinical Pathology. Pathology Patterns Reviews*, 118(Suppl 1), S100-S115.

- Patel, N. D., van Zante, A., Eisele, D. W., Harnsberger, H. R., & Glastonbury, C. M. (2011). Oncocytoma: the vanishing parotid mass. *American Journal of Neuroradiology*, 32(9), 1703-1706.
- Shah, V. N., & Branstetter IV, B. F. (2007). Oncocytoma of the parotid gland: a potential false-positive finding on ¹⁸F-FDG PET. *American Journal of Roentgenology*, 189(4), W212-W214.
- Shellenberger, T. D., Williams, M. D., Clayman, G. L., & Kumar, A. J. (2008). Parotid gland oncocytosis: CT findings with histopathologic correlation. *American Journal of Neuroradiology*, 29(4), 734-736.
- Tana, T. J., & Tana, T. Y., (2010). CT features of parotid oncocytomas: A case study of 10 cases and literature review. *American Journal of Neuroradiology*, 31, 1413-1417.
- Uzunkulaoglu, H., Yazici, H., Can, I. H., Dogan, S., & Uzunkulaoglu, T. (2012). Bilateral oncocytoma in the parotid gland. *The Journal of Craniofacial Surgery*, 23(3), e246-e247.
- Vlachaki, E., Tsapas, A., Dimitrakopoulos, K., Kontzoglou, G., & Klonizakis, I. (2009). Parotid oncocytoma: A case report. *Cases Journal*, 2, 6423.